ELSEVIER

Operative Techniques in
Orthopaedics

Rib-Based Anchors for Growing Rods in the Treatment of Early-Onset Scoliosis

Daniel J. Miller, MD, and Michael G. Vitale, MD, MPH

The treatment of early-onset scoliosis (EOS) has evolved substantially over the years. Traditional growing-rod constructs rely on spine-based fixation for proximal and distal anchor sites. Hybrid growing-rod constructs pair rib-based proximal anchors with spinal or pelvic anchors distally. Both traditional and hybrid growing-rod constructs can control spinal deformity in young patients with early-onset scoliosis while preserving spinal and thoracic growth. Proximal rib fixation has many theoretical and practical advantages over spine-based proximal anchors. This article discusses the indications, technique, and outcomes of proximal rib fixation in hybrid growing-rod constructs for early-onset scoliosis.
Oper Tech Orthop 26:241-246

KEYWORDS early-onset scoliosis, growing rods, rib anchors, growth sparing spinal instrumentation, scoliosis

Introduction

Goals of management in early-onset scoliosis (EOS) include controlling spinal deformity, optimizing thoracic growth, and maximizing function while minimizing complications and negative effects of treatment on quality of life.

Distraction-based constructs improve and control spinal deformity through application of distracting forces to the spine via proximal and distal anchors with intervening rod(s). As the child grows, the rod(s) are periodically lengthened to preserve deformity correction while maintaining growth of the spine and thorax.

Traditional growing-rod constructs rely on spine-based fixation for proximal and distal anchor sites. Correction of spinal deformity indirectly through rib-based instrumentation was first popularized by Campbell through his pioneering work developing the vertical expandable titanium rib prosthesis. Since that time, numerous "hybrid" constructs have been described, which pair rib-based proximal anchors with spinal or pelvic anchors distally.

Department of Orthopaedic Surgery, Columbia University Medical Center, New York, NY.

Address reprint requests to Michael G. Vitale, MD, MPH, Department of Orthopaedic Surgery, Pediatric Spine and Scoliosis Surgery, 3959 Broadway, Suite 8, North New York, NY 10032. E-mail: mgv1@cumc.columbia.edu

In this article, we describe the indications, technique, and outcomes of rib-based anchors for hybrid growing-rod constructs in EOS.

Advantages and Disadvantages of Hybrid Constructs

Proximal rib fixation has many theoretical and practical advantages over spine-based anchors. Rib hooks are relatively easy to place without reliance on fluoroscopy. Hooks are also placed far away from the spinal canal, whereas spine-based instrumentation carries an inherent risk of direct neurologic injury regardless of implant choice (hooks or screws). Abnormal pedicle morphology in the proximal thoracic spine of the young child may also make safe placement of pedicle screws challenging, if not impossible.

Growth-sparing constructs are intended to maximize growth potential of the spine and thorax. This point is particularly salient during the first 5 years of life when spinal growth and pulmonary maturation are highest. Traditional growing-rod constructs rely on fusion of cephalad and caudal anchors, which eliminate segmental growth and motion from these foundation levels. Furthermore, autofusion of uninstrumented levels is seen in over 80% of patients treated with traditional growing-rod constructs by the time of their spinal fusion (Fig. 1).[1] This progressive stiffness and autofusion phenomenon is thought to contribute to the law of

http://dx.doi.org/10.1053/j.oto.2016.09.006
1048-6666//

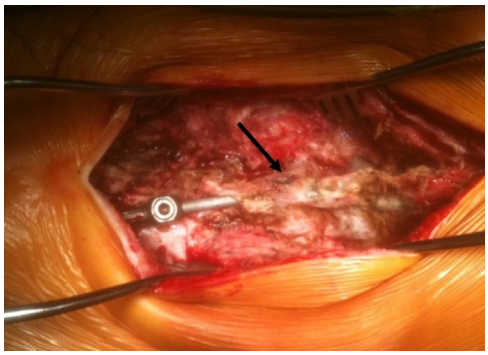

Figure 1 Autofusion of uninstrumented levels encountered during conversion of a growing-rod construct to definitive fusion.

diminishing returns observed with serial growing-rod lengthening.[2] In contrast, rib-based anchors avoid exposure of the proximal posterior spinal elements entirely. The rib-hook interface also affords a less-rigid construct with more mobility which may serve to decrease the risk of autofusion related to immobility.[3] Decreased construct rigidity has also been cited as a reason for the significantly decreased incidence of rod breakage in proximal rib constructs compared to proximal spine anchors.[4] In a retrospective review of 34 patients with rib-anchored hybrid growing rods and 142 traditional spine-anchored growing rods, Yamaguchi et al[5] found that rib-anchored growing rods had a significantly decreased risk of lifetime rod breakage compared with spine-anchored growing rods (6% vs 29%, $P = 0.041$).

In contrast to spinal fusion surgery where stress on multiple anchors dissipates with maturation of a fusion mass, anchors in growing-instrumentation constructs bear the entire load over a course of treatment. As such, anchor failure is much more common in growth-sparing constructs when compared to anchor failure in spinal fusion for adolescent idiopathic scoliosis (15%-40% vs 0.6%-1.5%).[6] Biomechanically, Akbarnia et al[6] found that rib-hook foundations have equal ultimate strength compared to screw foundations when evaluated in a porcine model.

Growing rods for EOS are complicated by a high rate of hardware prominence and infection.[7] Rib hooks provide a more robust soft tissue envelope for coverage when compared to the spine. This is particularly relevant to children with EOS, who often are malnourished with poor wound healing potential.[8]

Unique disadvantages of rib-based fixation include potential for pleural leak, rib fracture, or intercostal neurovascular injury; however, these are rarely reported.

Indications and Contraindications

Indications for growing spinal constructs include severe or progressive spinal deformity in a patient with significant growth remaining and in whom nonoperative management has either failed or is likely to fail. Often, these curves are greater than 50° and may progress rapidly. Contraindications to surgical intervention include patients whose perioperative medical risk is deemed unacceptable, patients with active infection or soft tissue compromise, patients with insufficient bone stock, or families who are unable to maintain appropriate clinical follow up.

Preoperative Planning

A multidisciplinary medical evaluation is essential for preoperative medical optimization to decrease the risk of perioperative complications. Nutrition is recognized to be a critical factor in wound healing and should be optimized preoperatively. Chlorhexidine wipes may be provided for application the night before surgery to decrease the risk of surgical site infection.

Full-length radiographs are scrutinized to identify anatomical anomalies and to plan correction strategies. Advanced imaging with preoperative magnetic resonance imaging is a requisite to evaluate for neuraxial abnormality.

In considering sites of cephalad and caudal foundations, each site must be capable of withstanding distractive forces over a prolonged period without mechanical failure or loosening. For rib-based foundations, our current practice is to use multiple rib anchors (eg, ≥ 5) at the T2-T4 levels. Sharing load among multiple rib anchor points decreases the chance of rib fracture or hardware migration. The first rib should be avoided given the close anatomical proximity of the lower brachial plexus and the risk of brachial plexus palsy.[9]

Lowest instrumented vertebrae should span the Cobb and allow the least amount of instrumented spine. The lumbar spine is most appropriate for most idiopathic patients (Fig. 2), but many patients with syndromic or neuromuscular scoliosis have early-onset pelvic obliquity requiring stabilization to the pelvis (Fig. 3).[10] Although there has been some historical concern about the effect of pelvic instrumentation on the marginal walker, careful attention to sagittal plane greatly limits any negative effect of pelvic instrumentation on gait.[11] If pelvic-based caudal foundations are chosen, they are anchored via iliac U or S hooks or screws. We tend to use iliac hooks in younger patients given their ease of placement with screws reserved for cases requiring more rigid control of pelvic obliquity.

Traditional growing rod and hybrid constructs are lengthened via small open surgical procedures, whereas new magnetically controlled growing rods (MCGR) are lengthened by application of an externally controlled, magnetic device in an outpatient setting.[12] Our preference is to use MCGR if patient size and sagittal alignment permits given the potential benefits related to fewer open surgical procedures. Contraindications to MCGR include the presence of a pacemaker or patients who would require magnetic resonance imaging during the treatment period.

Dual growing-rod constructs have been shown to provide improved initial deformity correction and are associated with fewer complications when compared to single rod

Figure 2 Example of a rib-to-spine hybrid growing-rod construct in a patient with idiopathic EOS.

constructs.[13] As such, we use dual rod constructs unless precluded by patient habitus or soft tissue envelope.

Surgical Technique

The patient is positioned prone on an OSI or Jackson table after the induction of general anesthesia. Neuromonitoring is used and includes both the upper and the lower extremities. A surgical time out is performed and preoperative antibiotics are administered within 1 hour of incision. Fluoroscopy is used to localize planned levels of instrumentation.

A single midline incision is made proximally and dissection is continued to the level of the fascia. Additional exposure continues off the midline, lateral to the posterior spinal elements. A J-shaped incision is made through the trapezius and rhomboids (Fig. 4). This muscular flap is elevated laterally over the erector spinae to their origin on the ribs with blunt dissection. The transverse processes and ribs are palpated through the paraspinal musculature. The erector spinae are then split lateral to the transverse processes, and dissection is continued directly down to the level of the rib (Fig. 5). Hook starters are used to prepare the undersurface of the rib (Fig. 6). Rib hooks are subsequently placed subperiosteally 1 cm lateral to the transverse process with care to avoid the neurovascular bundle coursing on the inferior aspect of the rib (Fig. 7). Following bilateral rib anchor placement, distal anchor foundations (lumbar or pelvic) are placed in the usual fashion. Rods are measured using fluoroscopic assistance and contoured in the coronal and sagittal plane. Careful premeasurement of rod length would allow correction during initial implantation.

A large Kelly clamp is used to create a submuscular tunnel for rod passage on the concavity of the curve. A chest tube is used to shuttle the rod through this channel to minimize trauma to the surrounding soft tissues (Fig. 8). Care is taken to avoid penetration of the retroperitoneum when passing instrument and implants submuscularly. The rod is provisionally secured first to the proximal anchor and then mated to distal foundation levels.

Correction is performed via distraction of the concave rod. Proximal rib fixation is sequentially tensioned multiple times

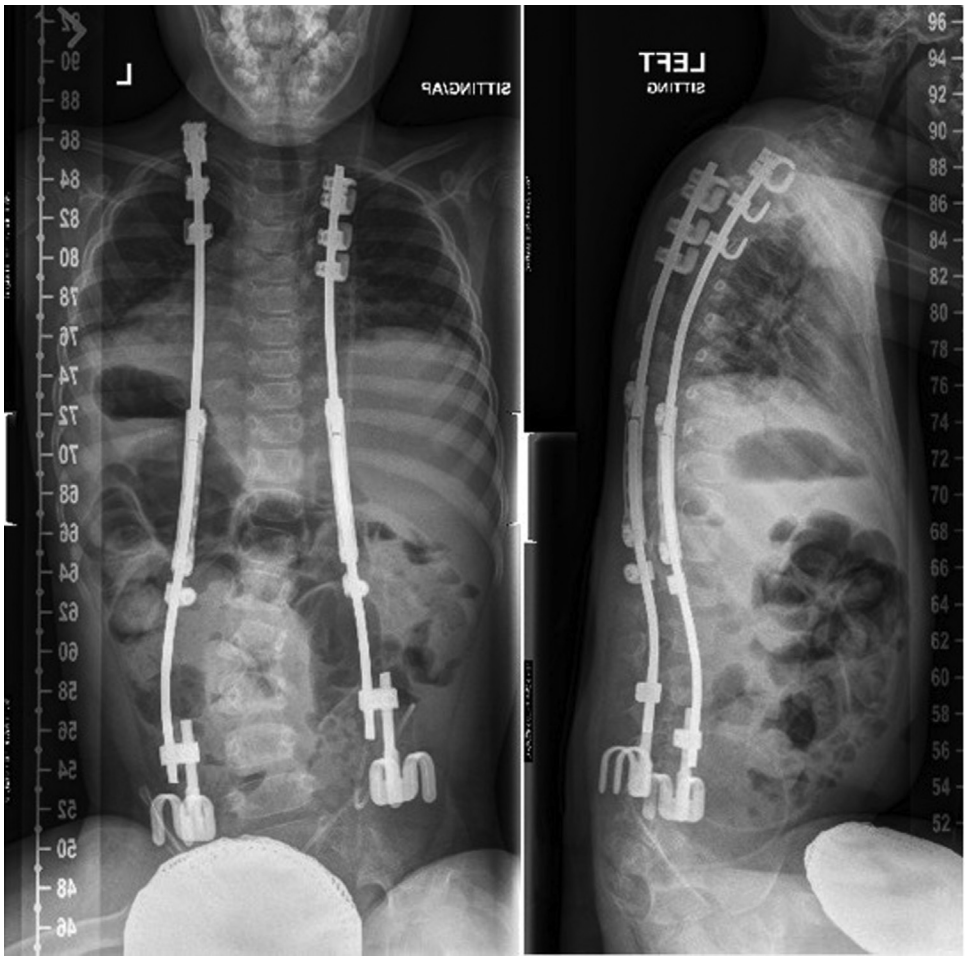

Figure 3 Example of a rib-to-pelvis hybrid growing-rod construct in a patient with neuromuscular EOS and pelvic obliquity.

and locked (Fig. 9). This is followed by tensioning and locking of distal fixation. An identical process is used for passage and tensioning of the contralateral, convex rod. Ensuring that rod connectors are at the same level facilitates future lengthening procedures (both open and magnetic). Following correction, the connectors are locked, and the rods are securely fastened to the foundation levels.

Biplanar imaging should confirm hardware placement and spinal alignment before final tightening. A high-speed burr is used at distal spinal foundation levels to promote fusion. Copious irrigation with a betadine soak is performed. Wound closure is performed in a layered fashion with the optional use of deep or superficial drains.

Postoperative management

Perioperative antibiotics are continued for 24 hours for surgical prophylaxis. Physical therapy begins on postoperative day 1 without restrictions. Patients are discharged home when

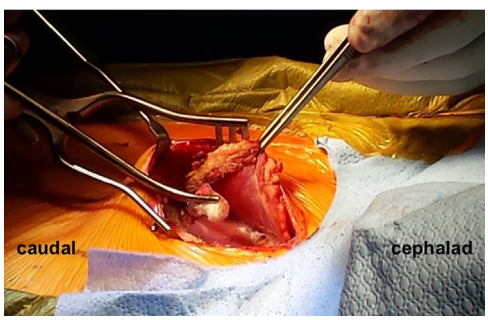

Figure 4 A flap is elevated using a J-shaped incision through the trapezius and rhomboids, and dissection is carried laterally over the erector spinae to their origin on the ribs.

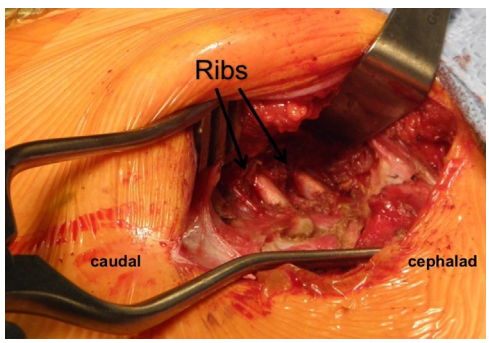

Figure 5 The erector spinae are split to expose the underlying bone for rib anchor placement.

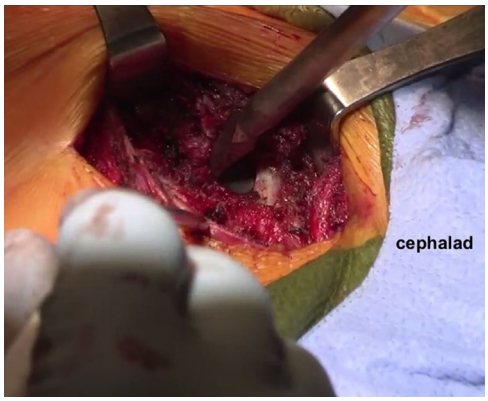

Figure 6 Hook starters are used to prepare the undersurface of the rib. (Color version of figure is available online.)

mobility and comfort allows. A wound check is scheduled 7-14 days following surgery.

Clinical and radiographic follow-up is continued every 4-6 months to monitor spinal and hardware alignment. Open lengthening procedures are performed every 6-12 months based on patient age, growth velocity, and surgeon preference. For MCGR constructs, outpatient lengthening procedures are performed monthly. Amount of lengthening performed at each visit is tailored to the patient's age, curve pattern, and expected spinal growth velocity.

Following skeletal maturity, patients are most often converted to a spinal fusion, though there is some interest in attempting to avoid exchange instrumentation and formal fusion in select patients.

Outcomes

Outcomes data on proximal rib fixation for hybrid growing rods are few in light of the fact that this is a newly developed technique for a relatively rare condition.

The earliest dedicated series of hybrid growing-rod constructs with proximal rib anchors was reported by Myung et al. In that review of 28 patients (23 single rod constructs and 5 dual rod constructs), complications were encountered in 7 patients including 9 instances of rib anchor failure.[14]

Figure 8 A chest tube is used to shuttle the rod through this channel to minimize trauma to the surrounding soft tissues. (Color version of figure is available online.)

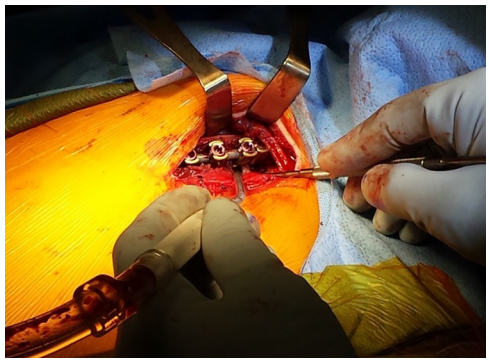

Figure 9 Proximal rib fixation is sequentially tensioned multiple times and locked. (Color version of figure is available online.)

Interestingly, all patients who had complications had a diagnosis of congenital scoliosis. Loss of rib fixation was not seen in any patients with 4 more proximal rib anchors. Average curve correction at index surgery was 19°, and correction was maintained through latest follow-up in all patients. No instances of neurologic injury were reported.

Vitale et al reviewed a prospective cohort of 106 patients treated with growing rods (73 with rib-based proximal anchors and 33 with spine-based proximal anchors). They found no difference between rib-based and spine-based proximal anchors in terms of curve correction, proximal device migration, or change in quality of life as measured by EOS

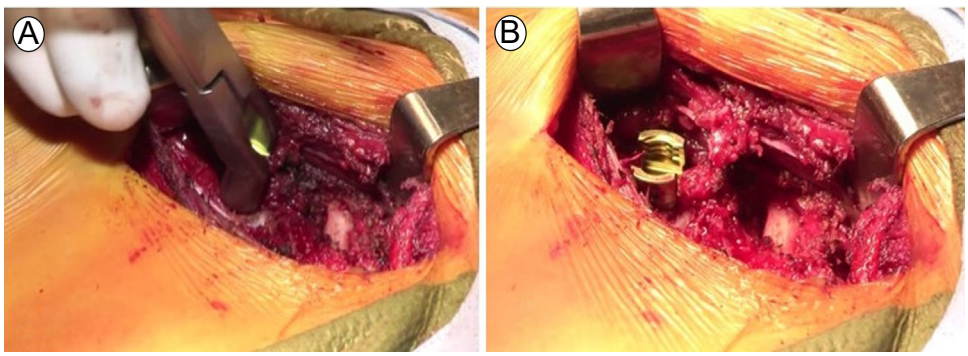

Figure 7 Rib hooks are placed subperiosteally 1 cm lateral to the transverse process. (Color version of figure is available online.)

Questionnaire (EOSQ-24).[15] Similar to previous work by Myung et al, having more proximal anchors (5 or more in this series) was found to be protective against proximal device migration.

Summary

Rib-based anchors for hybrid growing-rod constructs can control spinal deformity in young patients with EOS. These constructs have a favorable risk profile when compared to traditional growing-rod constructs. Use of multiple proximal anchors appears protective against anchor failure. Further research would help improve our understanding regarding the benefits, complications, and indications for hybrid growing-rod constructs.

References

1. Flynn JM, Tomlinson LA, Pawelek J, et al: Growing-rod graduates: Lessons learned from ninety-nine patients who completed lengthening. J Bone Joint Surg Am 95:1745-1750, 2013
2. Sankar WN, Skaggs DL, Yazici M, et al: Lengthening of dual growing rods and the law of diminishing returns. Spine 36:806-809, 2011
3. Skaggs DL: Hybrid distraction-based growing rods. In: Akbarnia BA, Yazici M, Thompson GH (eds): The Growing Spine: Management of Spinal Disorders in Young Children. Springer Berlin, Heidelberg; 601-612, 2010
4. Yamaguchi KS, Skaggs DL, Myung, KS, et al.: Proximal rib anchors have 77% less risk of rod breakage than proximal spine anchors in growing rods. American Acadmey of Orthopaedic Surgeons (AAOS) Annual Meeting, New Orleans, LA, 2014.
5. Yamaguchi Jr KT, Skaggs DL, Mansour S, et al: Are rib versus spine anchors protective against breakage of growing rods? Spine Deformity 2:489-492, 2014
6. Akbarnia BA, Yaszay B, Yazici M, et al. Biomechanical evaluation of 4 different foundation constructs commonly used in growing spine surgery: Are rib anchors comparable to spine anchors? Spine Deformity.2 (6):437–443.
7. Kabirian N, Akbarnia BA, Pawelek JB, et al: Deep surgical site infection following 2344 growing-rod procedures for early-onset scoliosis: Risk factors and clinical consequences. J Bone Joint Surg Am 96:e128, 2014
8. Myung KS, Skaggs DL, Thompson GH, Growing Spine Study Group, et al: Nutritional improvement following growing rod surgery in children with early onset scoliosis. J Child Orthop 8:251-256, 2014
9. Joiner ER, Andras LM, Skaggs DL: Mechanisms and risk factors of brachial plexus injury in the treatment of early-onset scoliosis with distraction-based growing implants. J Bone Joint Surg Am 95: e161, 2013
10. Sponseller PD, Yang JS, Thompson GH, et al: Pelvic fixation of growing rods: Comparison of constructs. Spine 34:1706-1710, 2009
11. Smith JT: Bilateral rib-to-pelvis technique for managing early-onset scoliosis. Clin Orthop Relat Res 469:1349-1355, 2011
12. Cheung KM, Cheung JP, Samartzis D, et al: Magnetically controlled growing rods for severe spinal curvature in young children: A prospective case series. Lancet 379:1967-1974, 2012
13. Thompson GH, Akbarnia BA, Kostial P, et al: Comparison of single and dual growing rod techniques followed through definitive surgery: A preliminary study. Spine 30:2039-2044, 2005
14. Myung KS, Skaggs DL, Yazici M, et al: Hybrid growth rods using spinal implants on ribs: Paper #85. Spine J Meet Abstr:105-106, 2010
15. Vitale MG, Matsumoto H, Feinberg N, et al: Paper #35 proximal rib vs proximal spine anchors in growing rods: A multicenter prospective cohort study. Spine Deformity 3:626-627, 2015